

Antegrade Intimal and Subintimal Angioplasty



Osami Kawarada, MD, FSCAI
Department of Cardiovascular Medicine
National Cerebral and Cardiovascular Center
Osaka, Japan

Multivessel Long Occlusive Disease

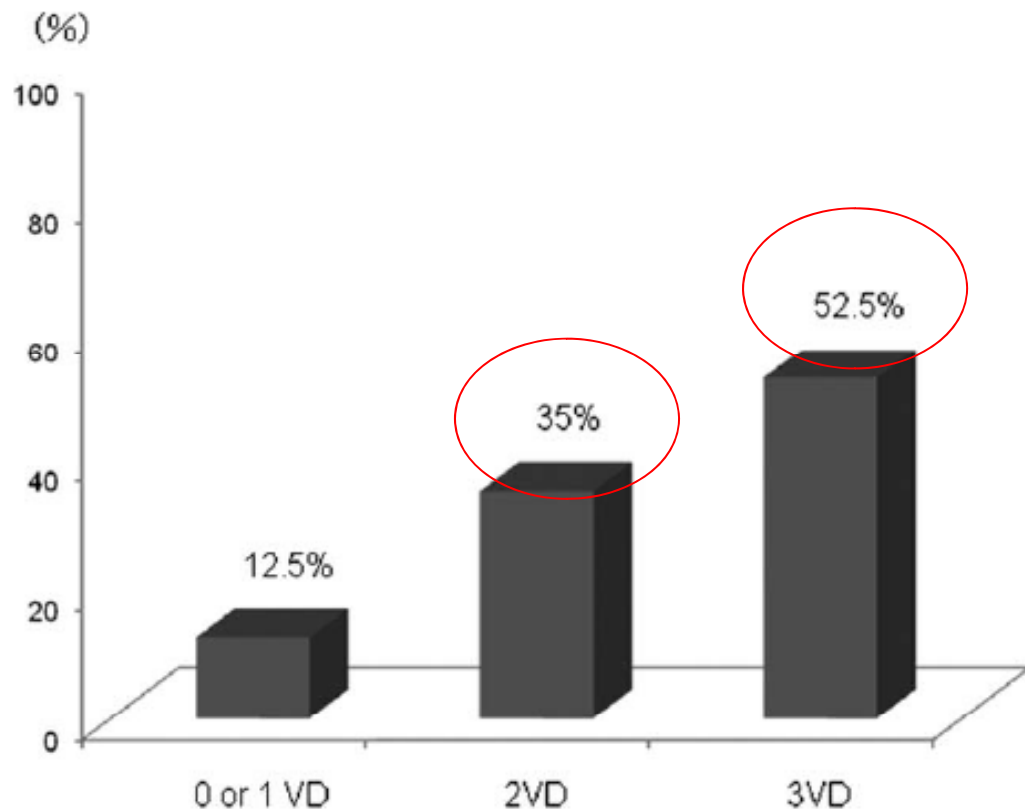
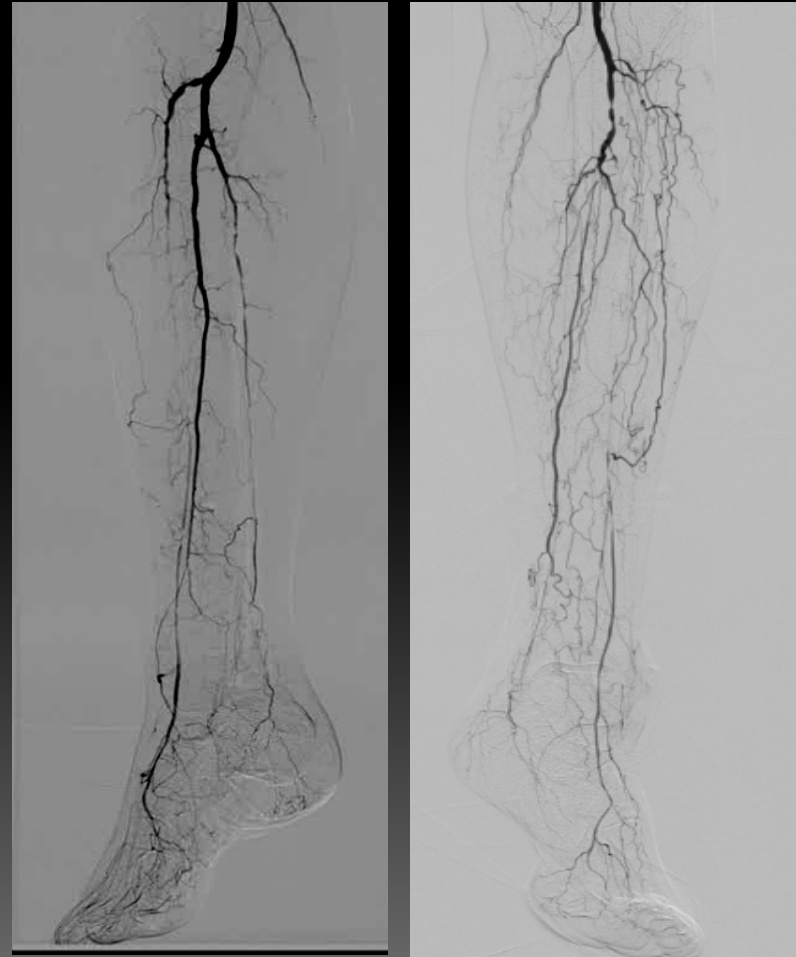
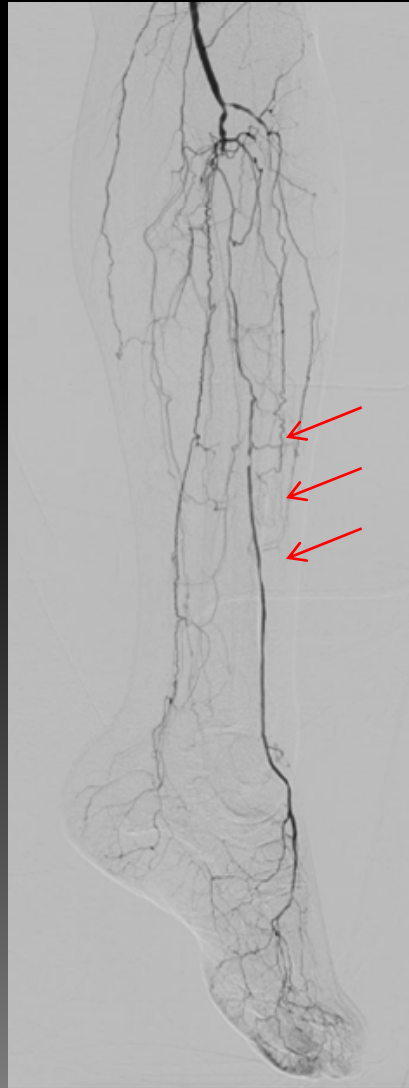

Fig. 3. Extent of crural artery disease. VD, vessel disease.

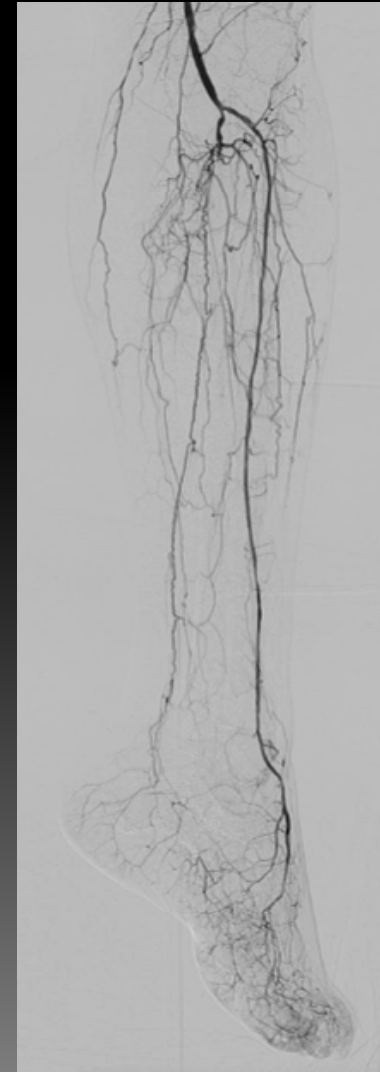


One Straight-Line flow

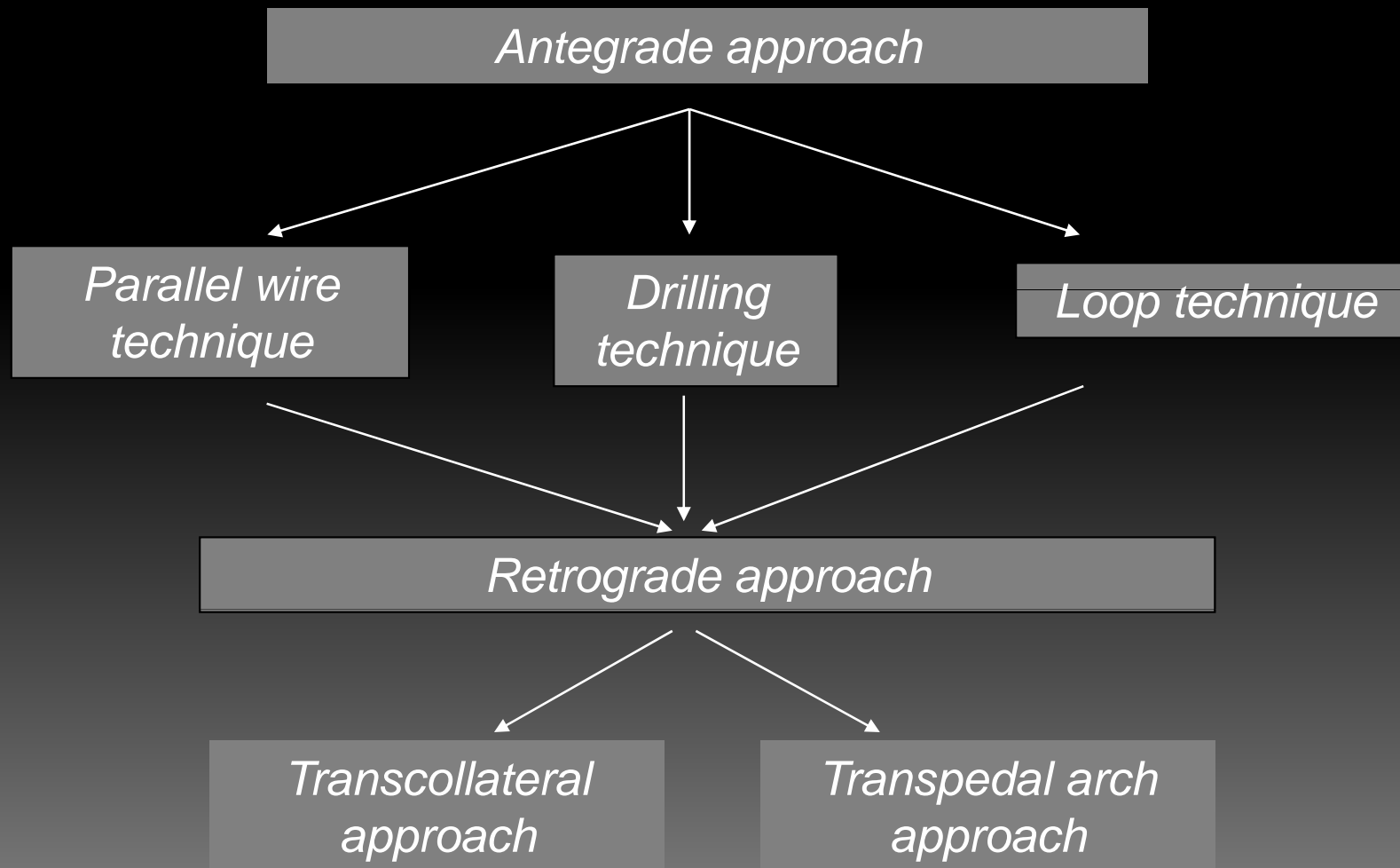
Pre



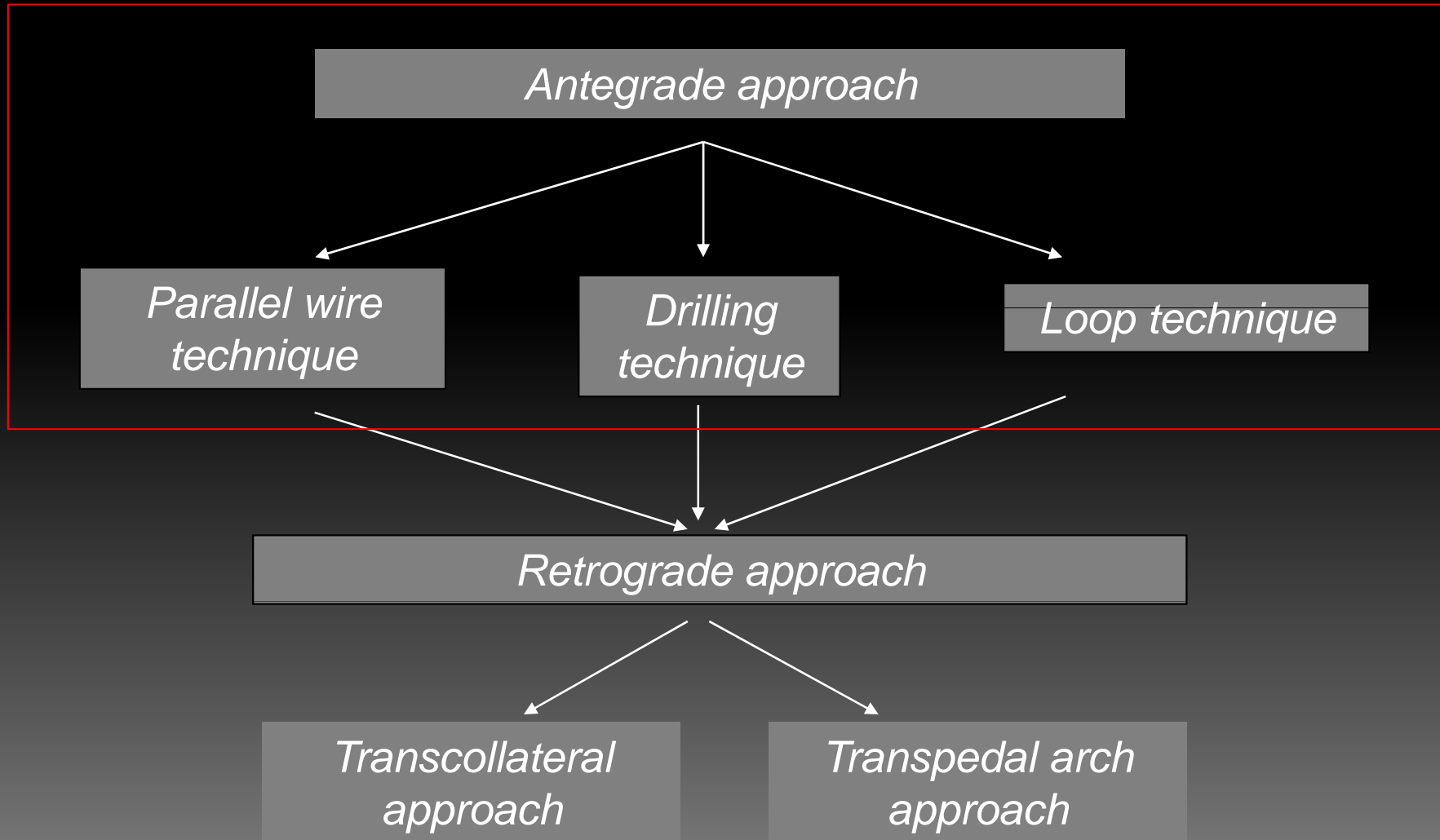
Post



Procedural Steps of Infrapopliteal CTO Crossing Technique



Procedural Steps of Infrapopliteal CTO Crossing Technique



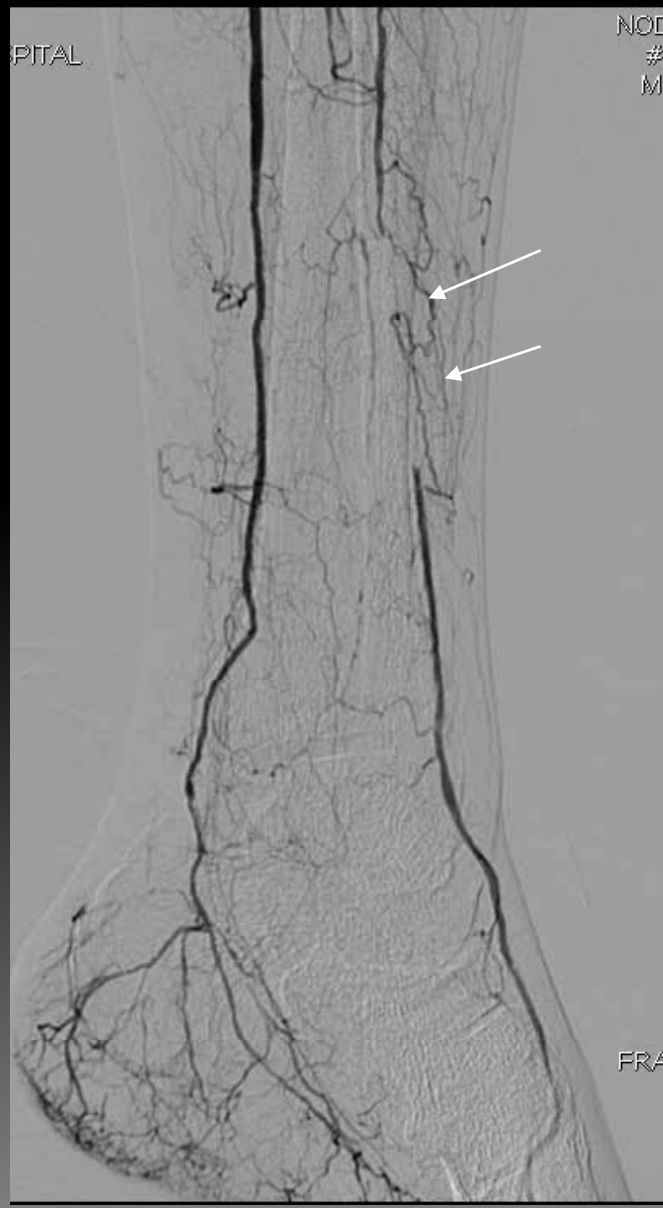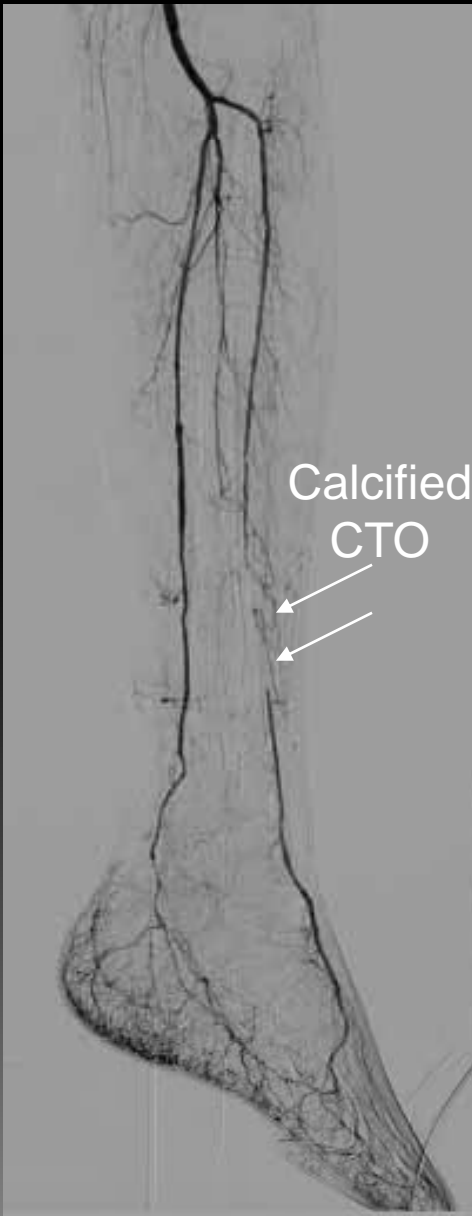
Tool Box : Infrapopliteal CTOs Intervention

- *Ipsilateral antegrade approach*
- *4F “long” sheath (30-45cm)*
- *0.014 > 0.010 or 0.018 inch guidewire*
- *OTW balloon catheter > microcatheter*

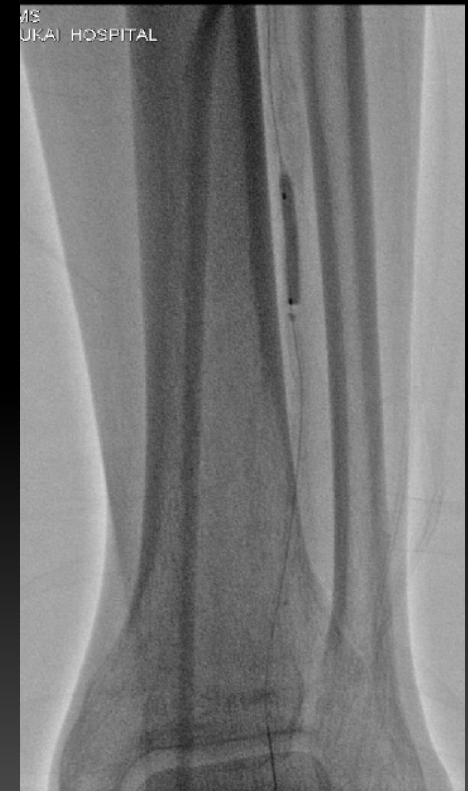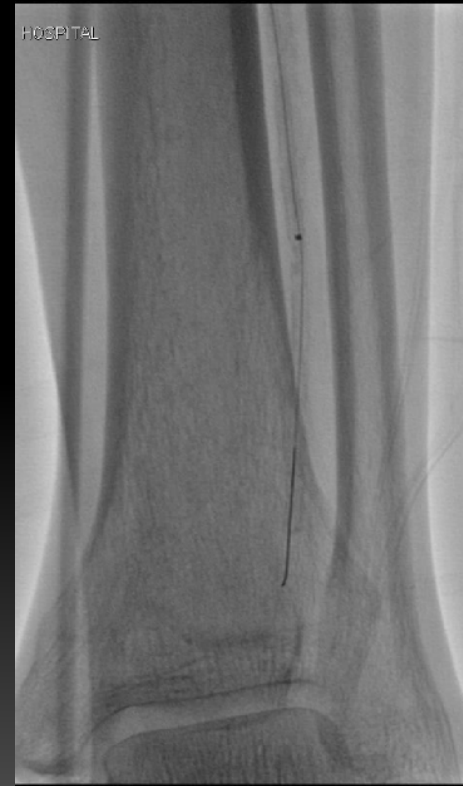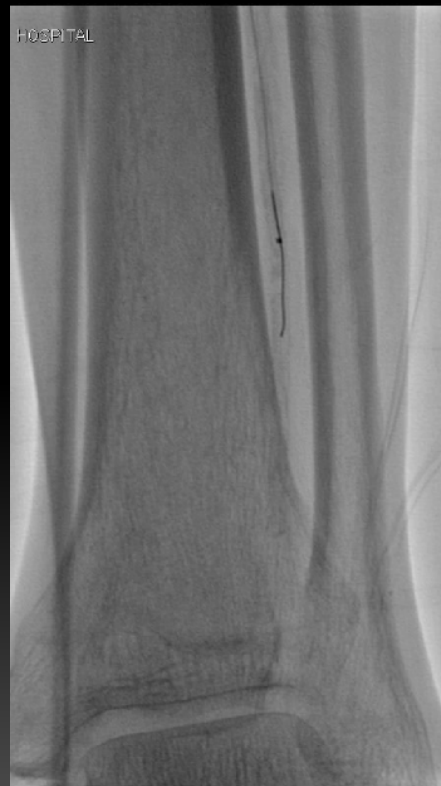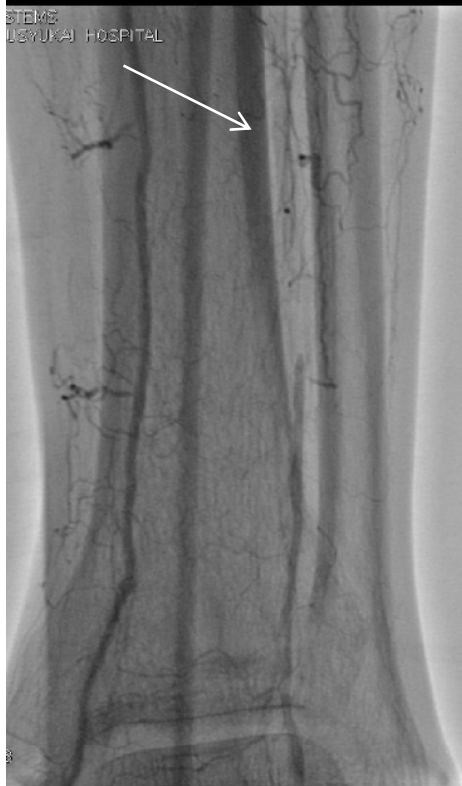
CTO Recanalization Technique 1
Conventional Coronary Technique

54 years/old, Male, Rutherford5, HD

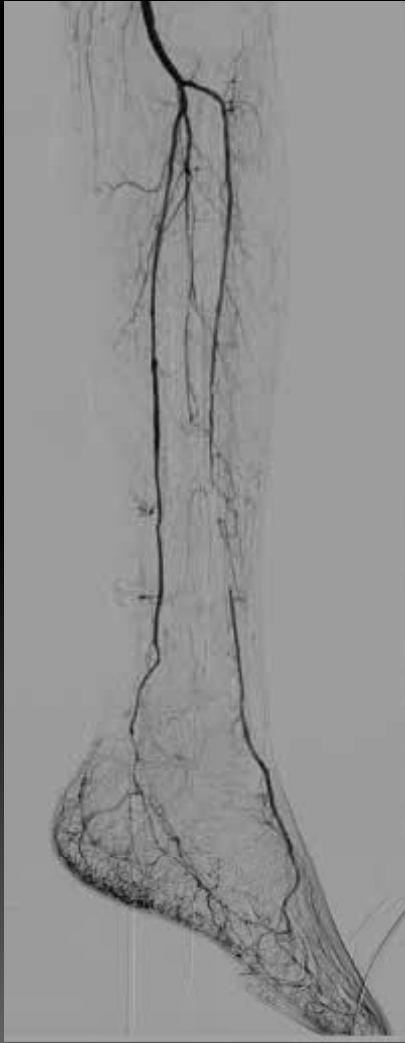Pre



0.014 CTO GW supported by OTW

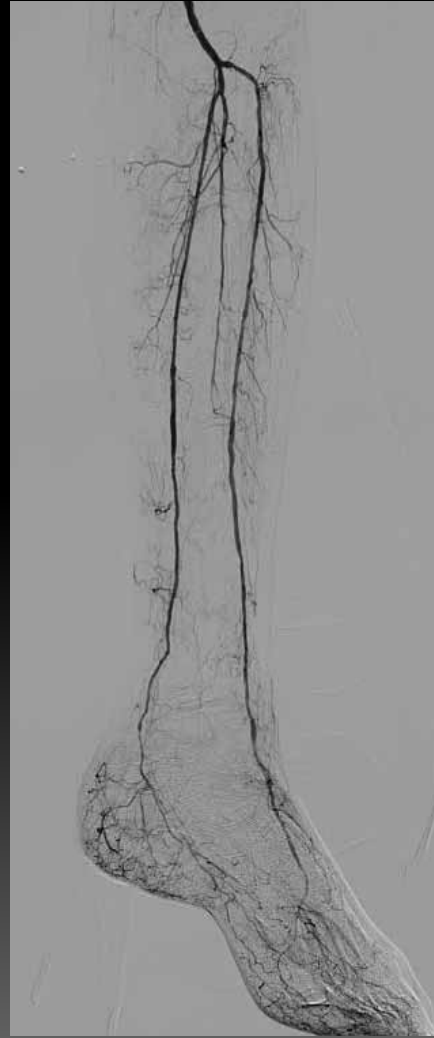


Pre



SPP
24/25 mmHg

Post



SPP
60/74 mmHg

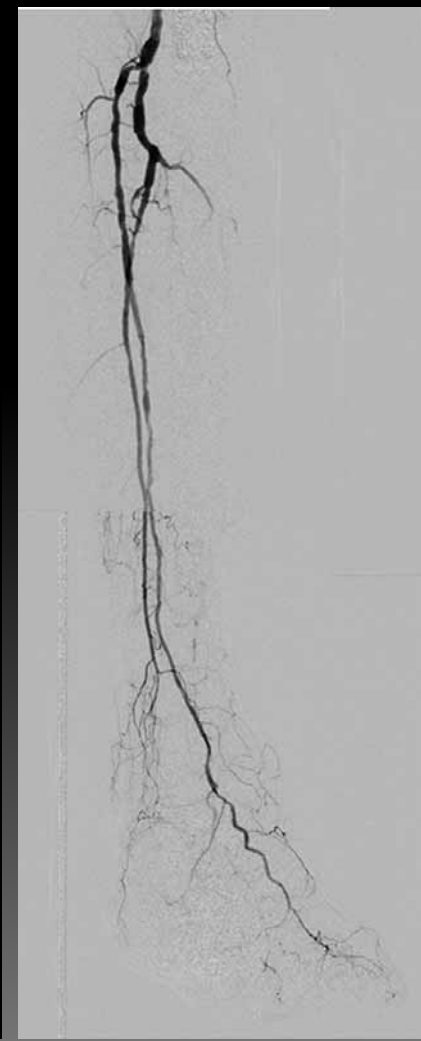
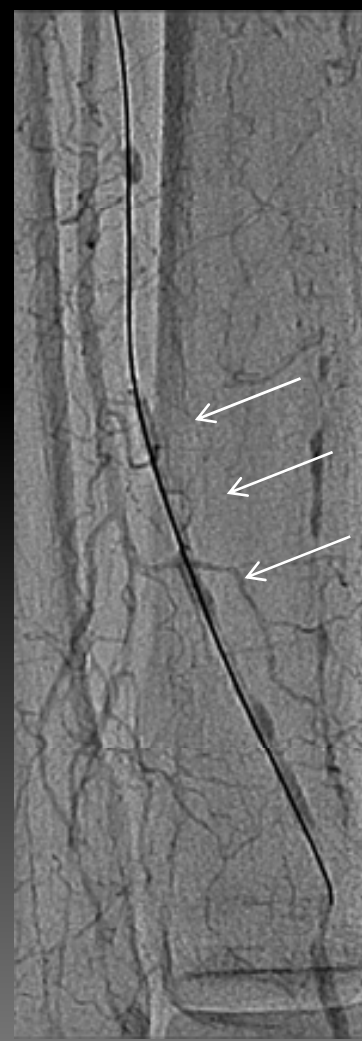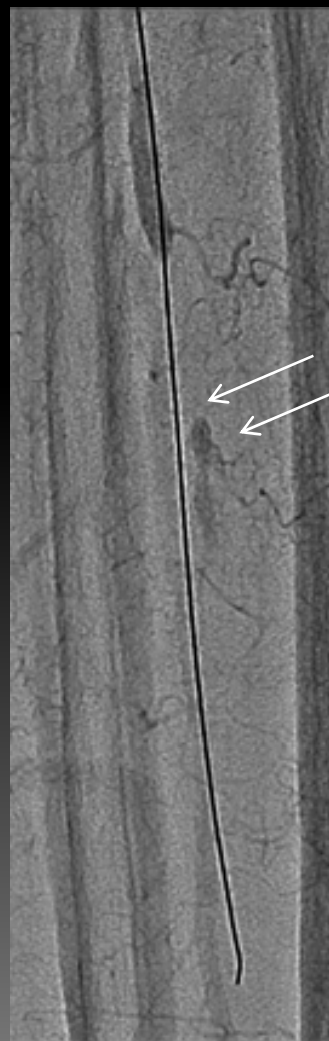
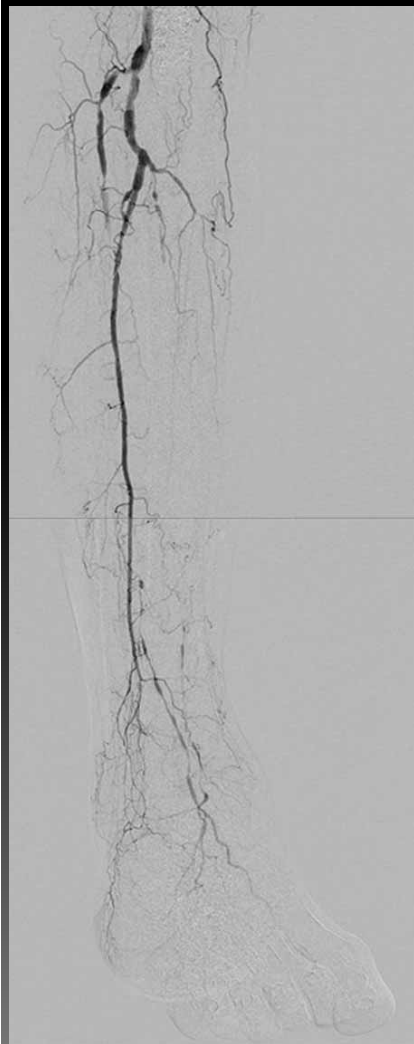
CTO Recanalization Technique 2
Parallel Wire Technique

Pre

1st GW

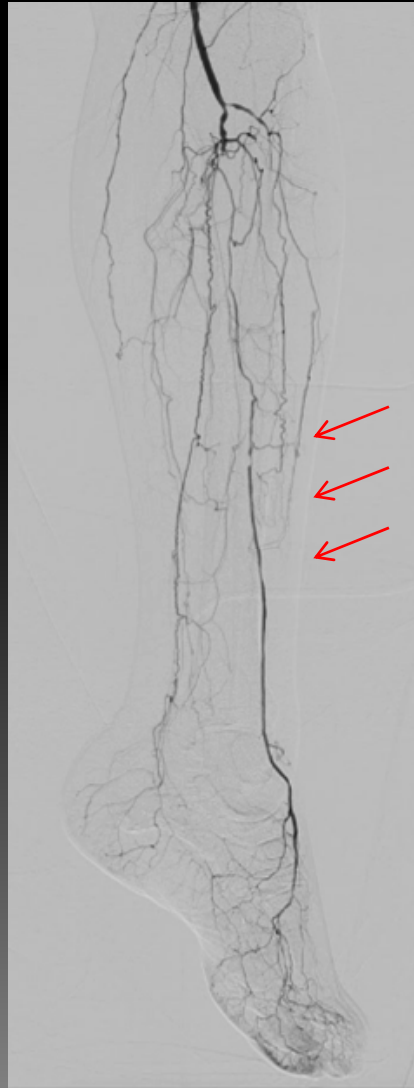2nd GW

Post

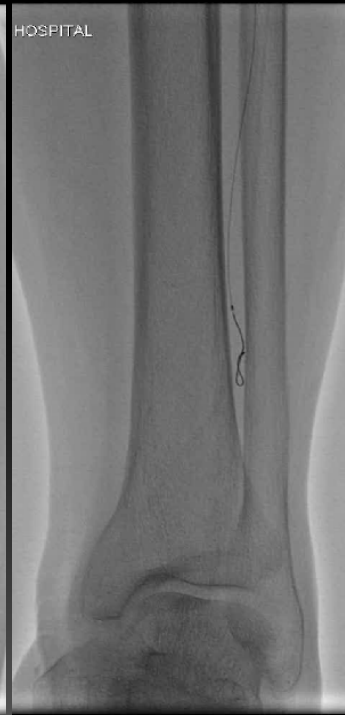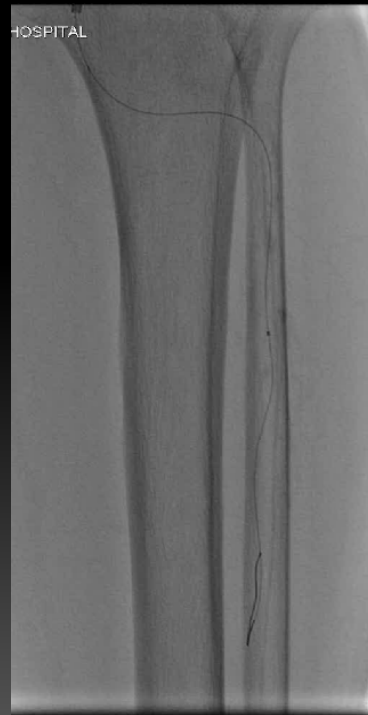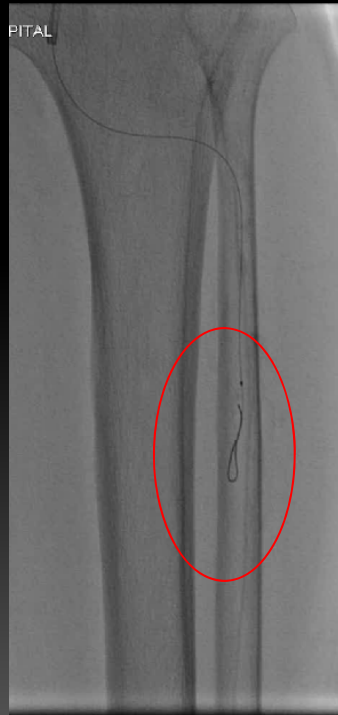


CTO Recanalization Technique 3
Loop Technique
(Subintimal angioplasty, Knuckle wire)

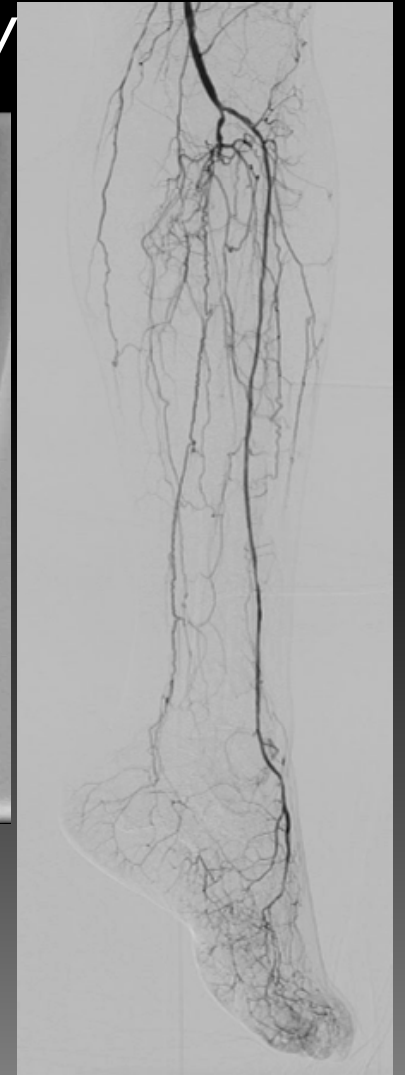Pre



0.014 "floppy" GW supported by OTW



Post



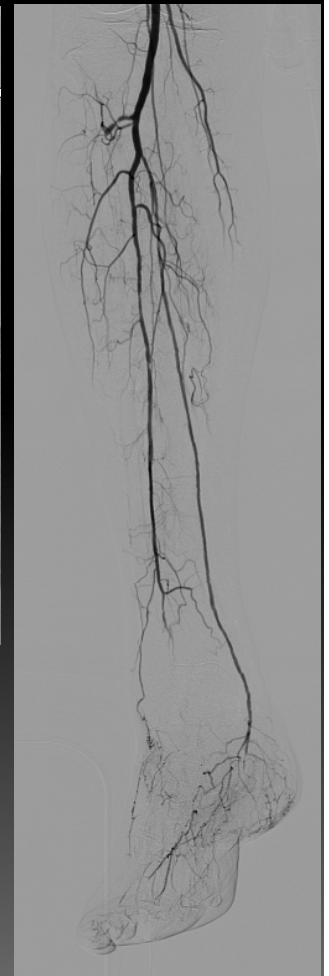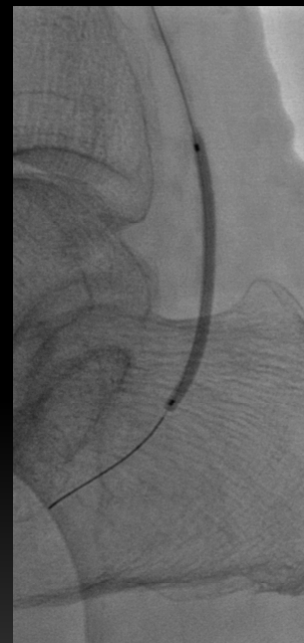
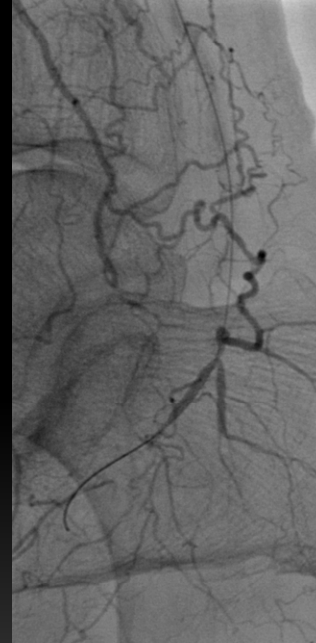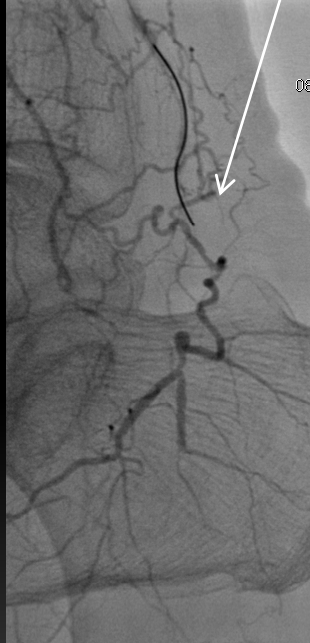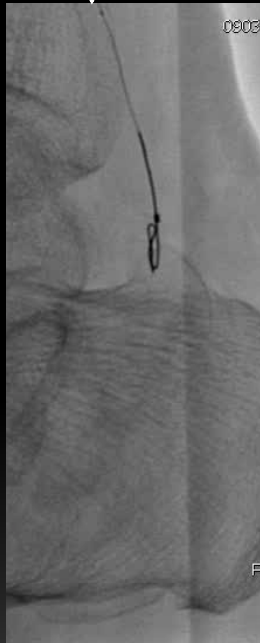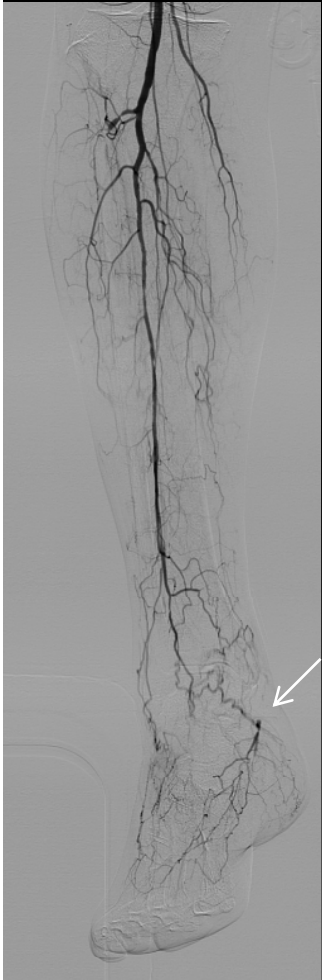
***CTO Recanalization Technique 4
Penetration Technique***

Pre

Loop technique

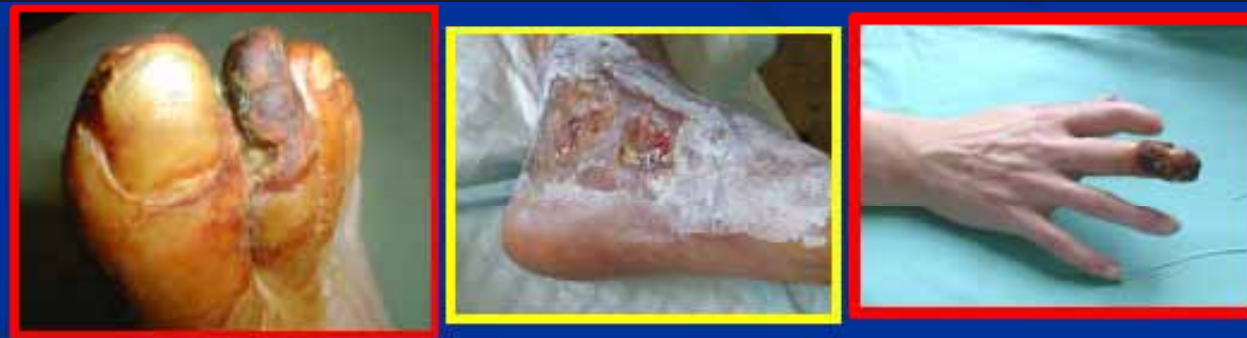Penetration

Post



- ✓ *Endovascular procedure has significantly developed during the last decade.*
- ✓ *The combination of these techniques can make a huge difference in the treatment of infrapopliteal CTOs.*

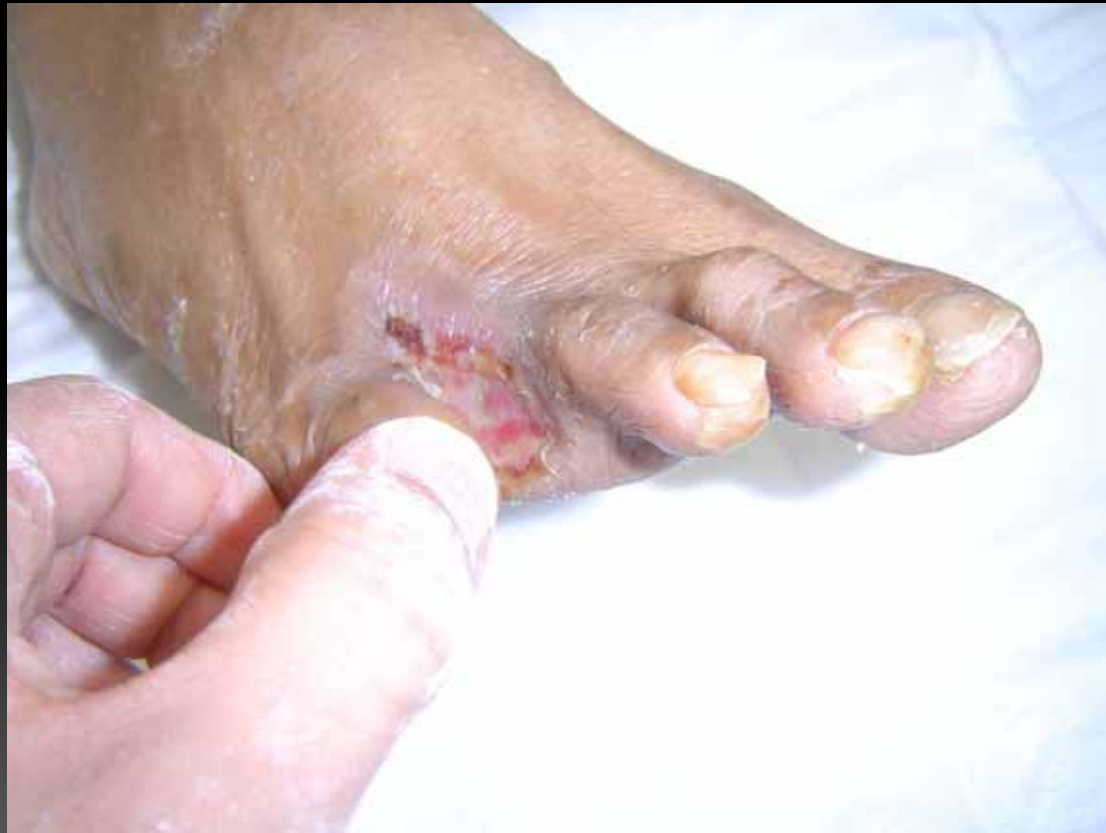Buerger's Disease



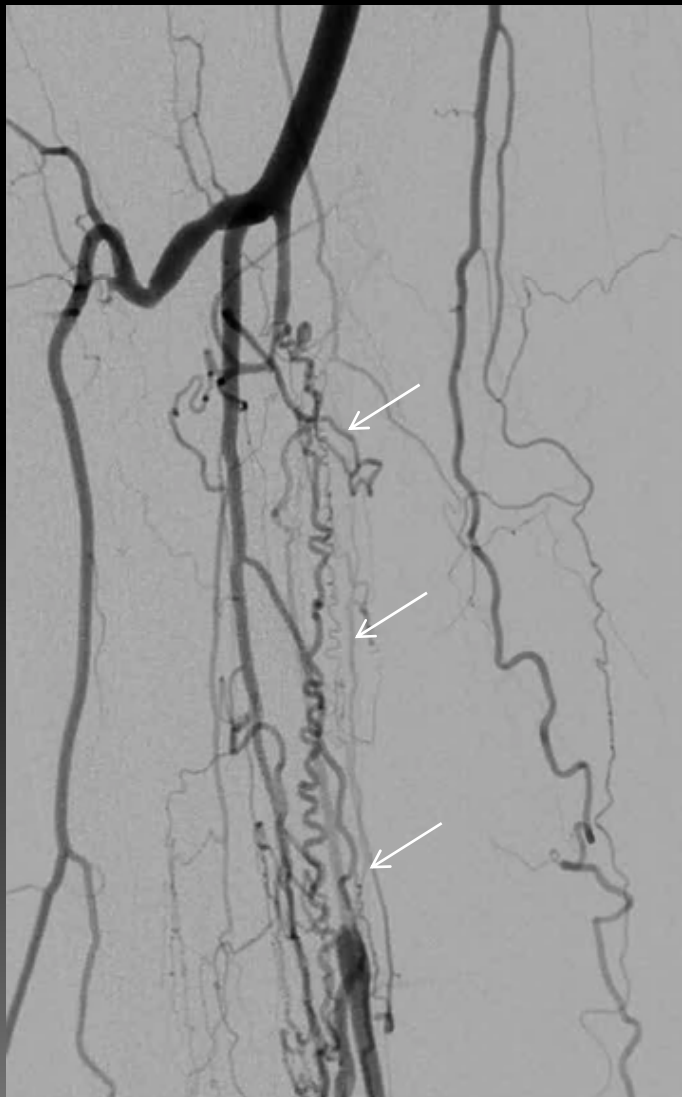Non-atherosclerotic disease, Buerger's disease patients might be able to enjoy endovascular therapy.

37 y/o Male, Smoker, Buerger's Disease

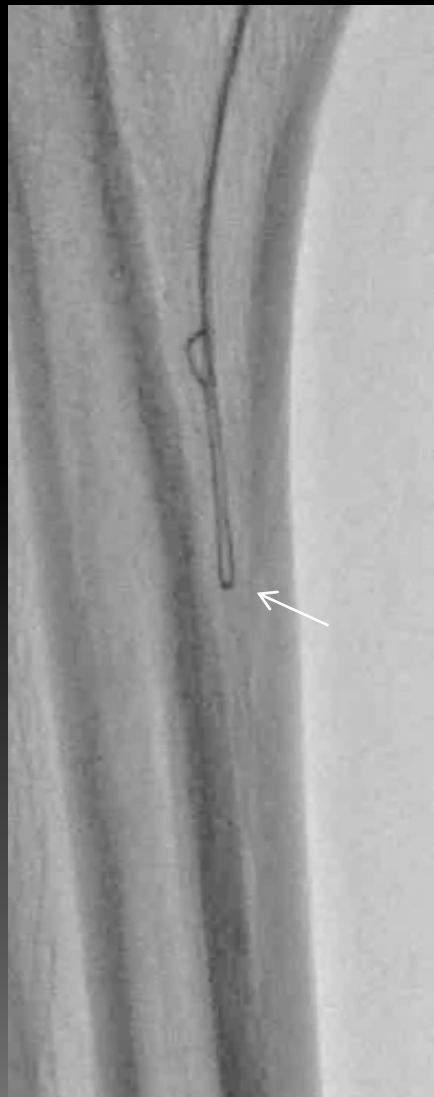2007



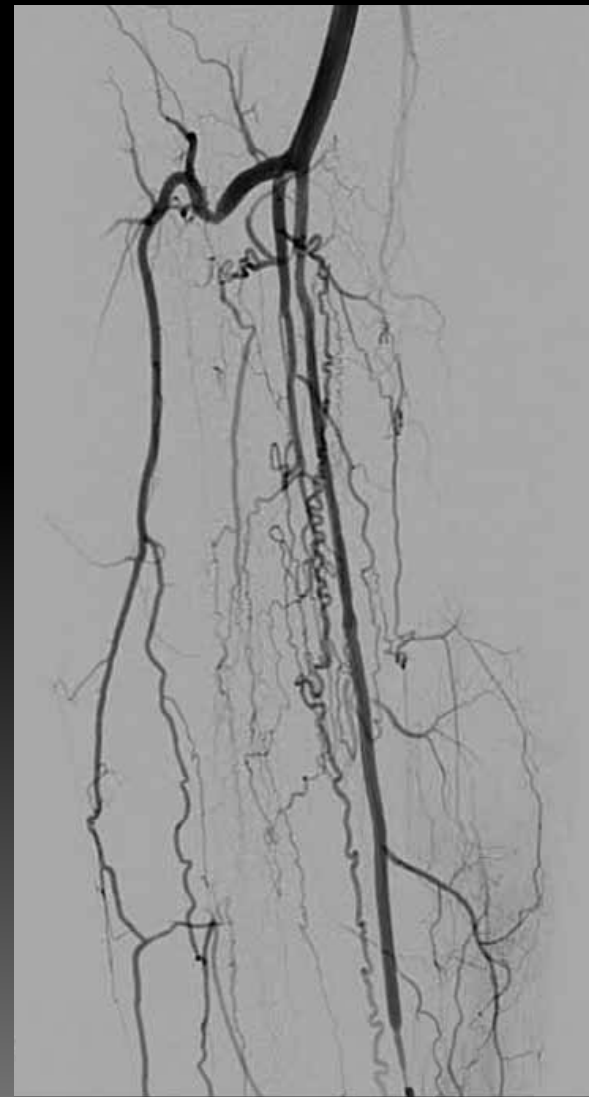
Pre



Loop technique



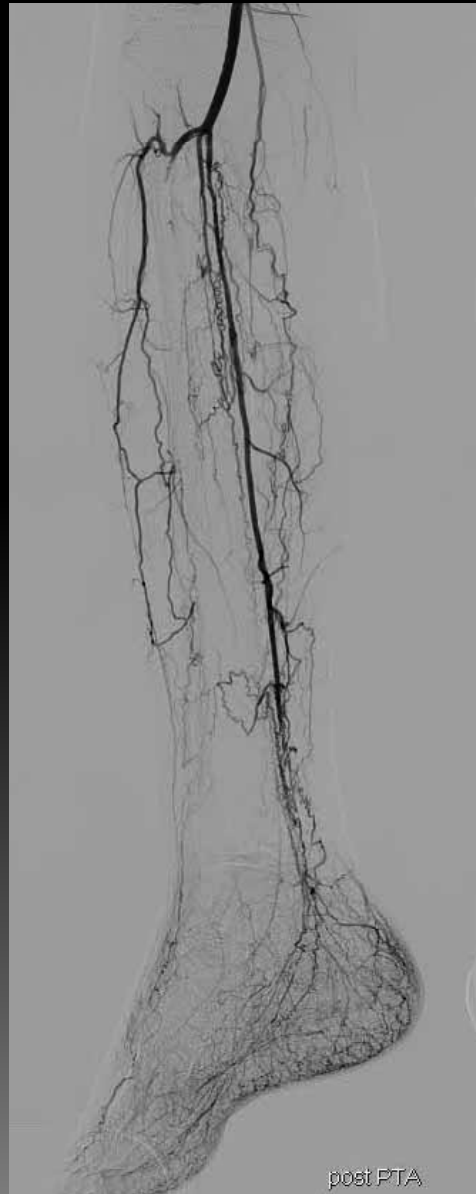Post



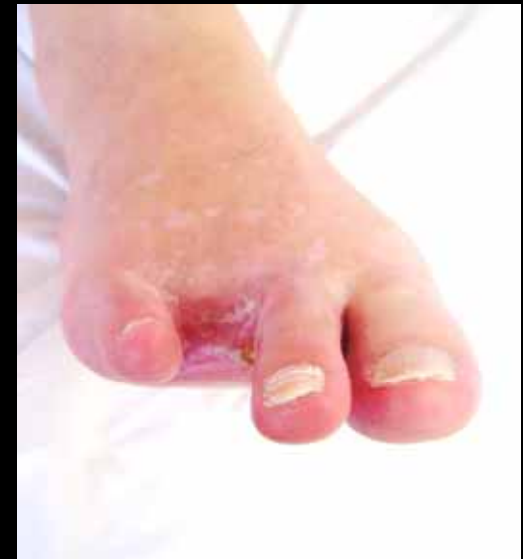Pre



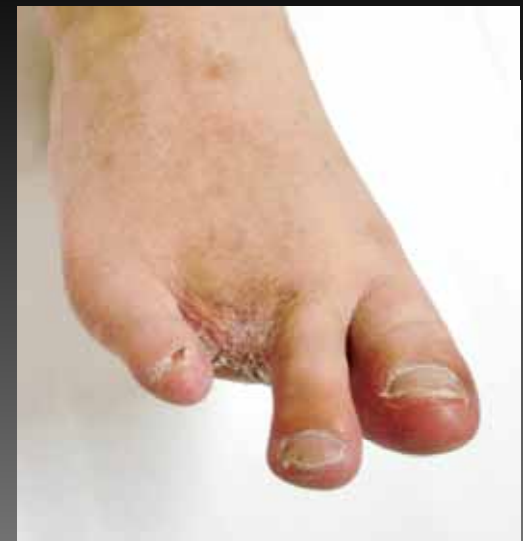Post



3 months

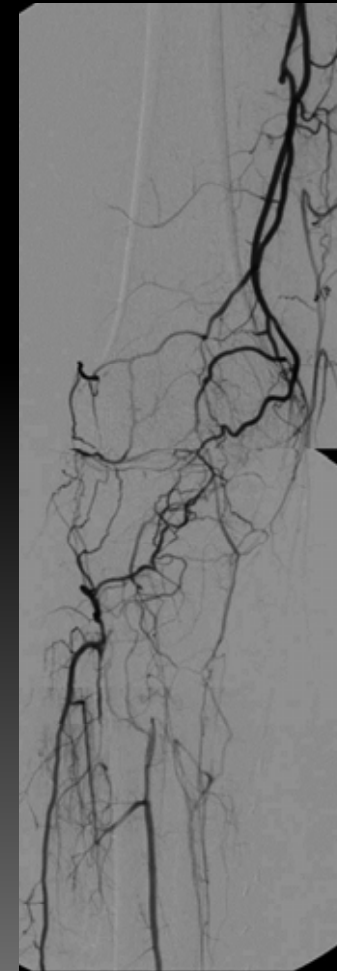
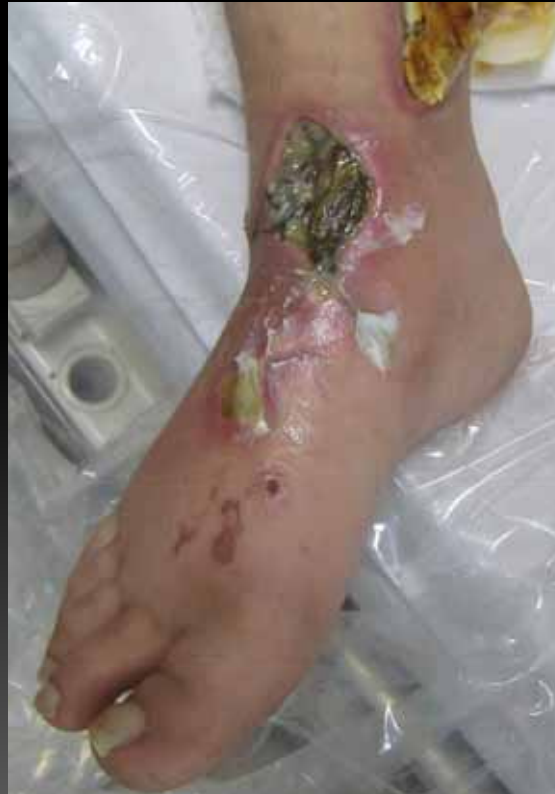
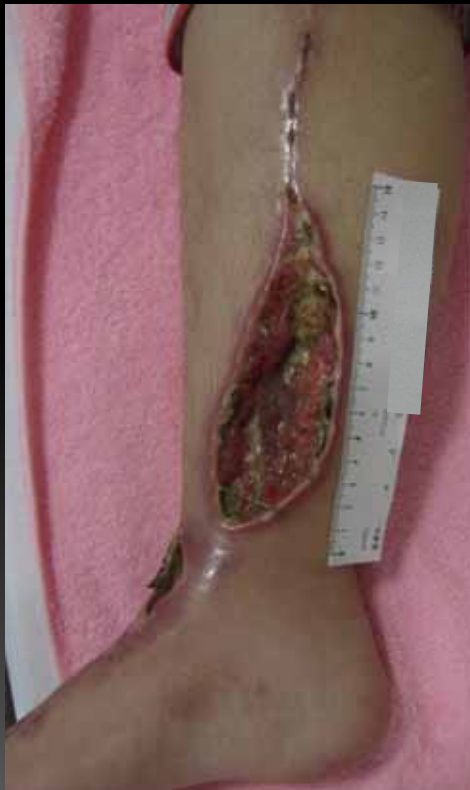
4 years



38 y/o Female, Smoker, Buerger's Disease

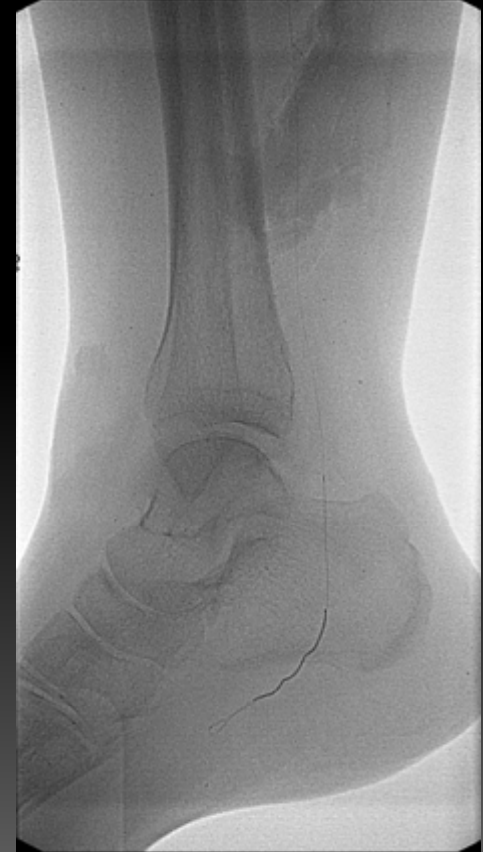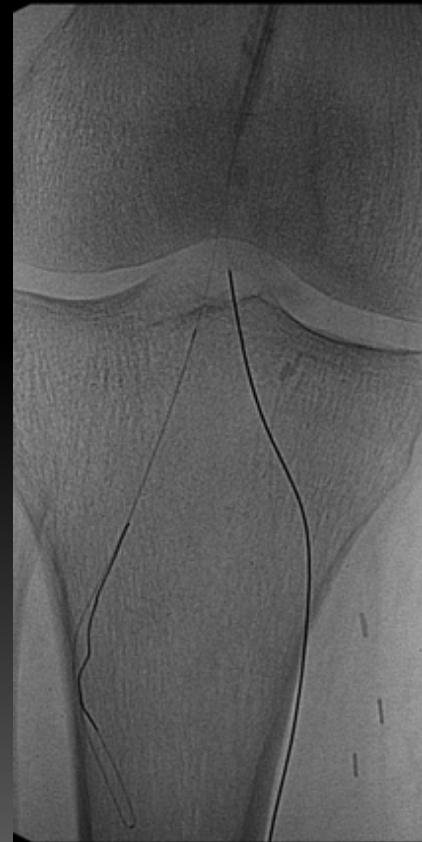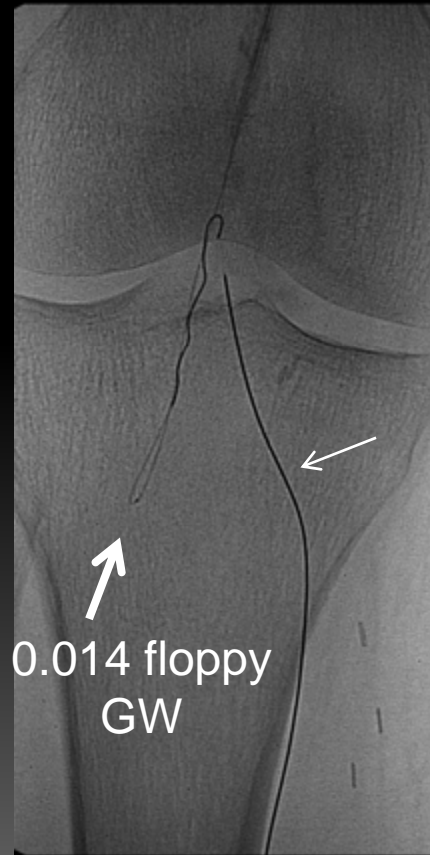
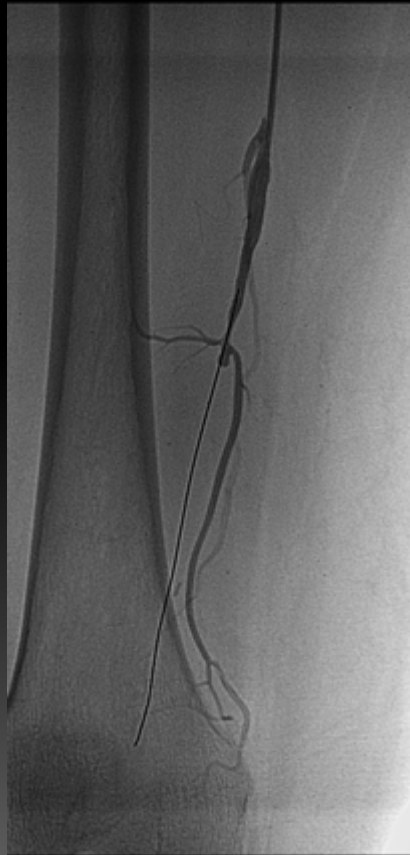
Extensive tissue loss after distal bypass occlusion



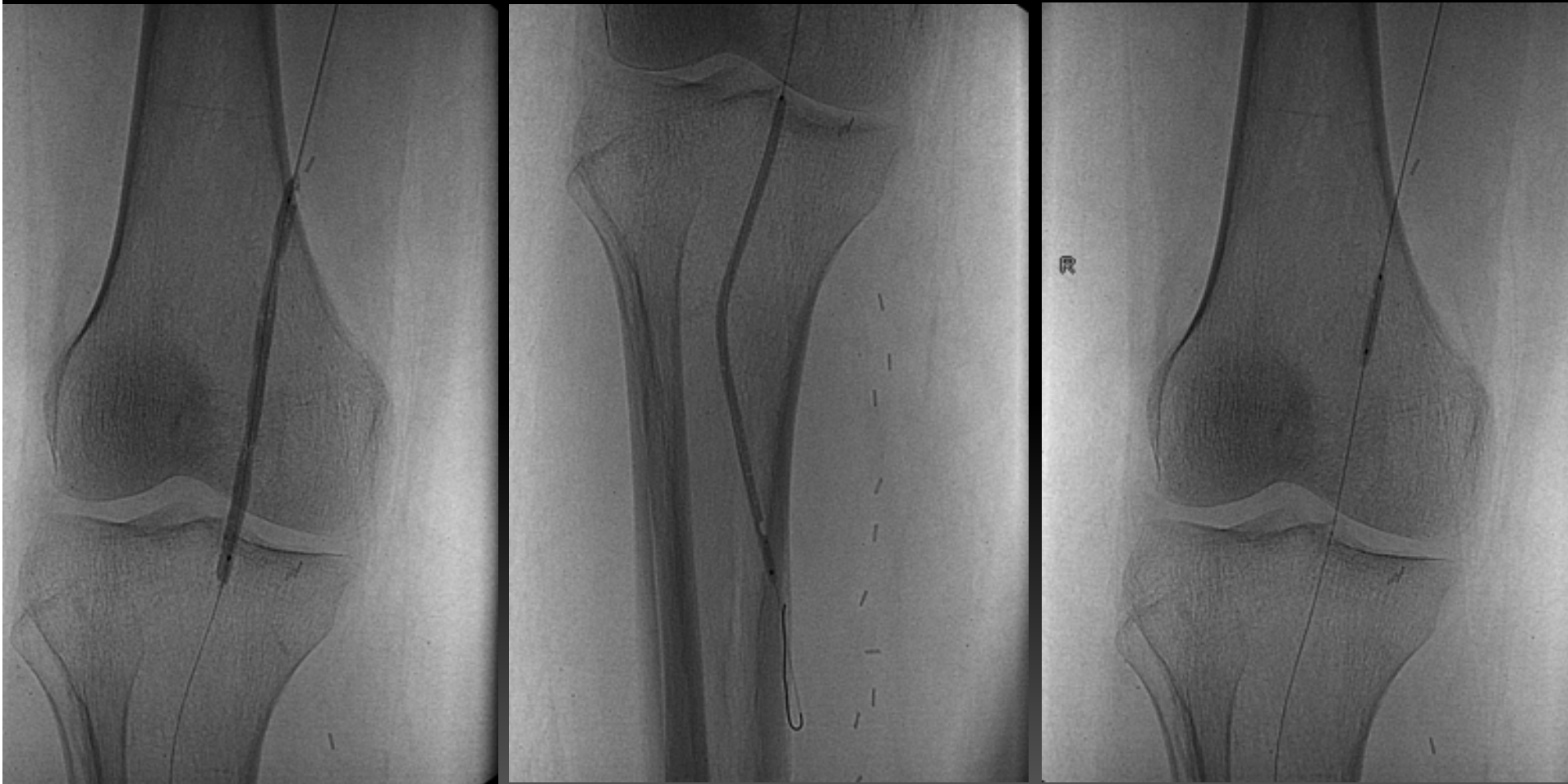Kawarada O, et al. J Endovasc Ther 2013 (in press)

Standard

Loop

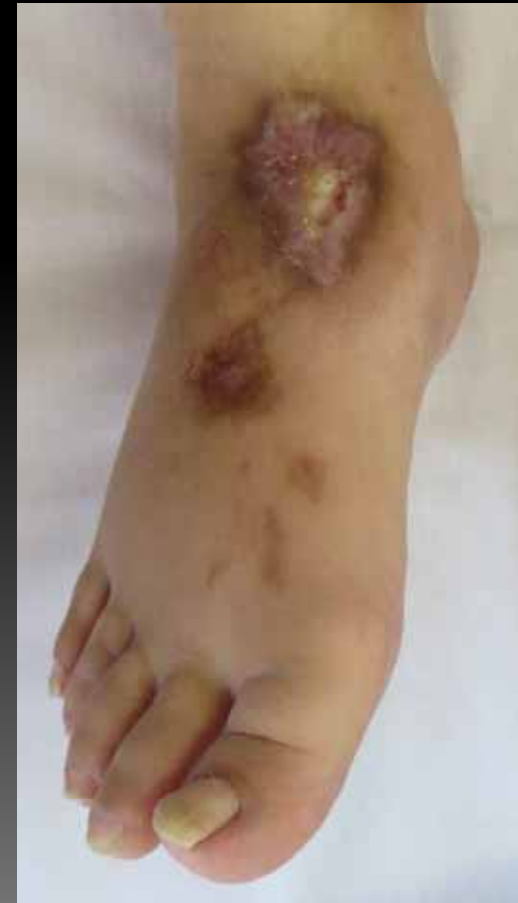
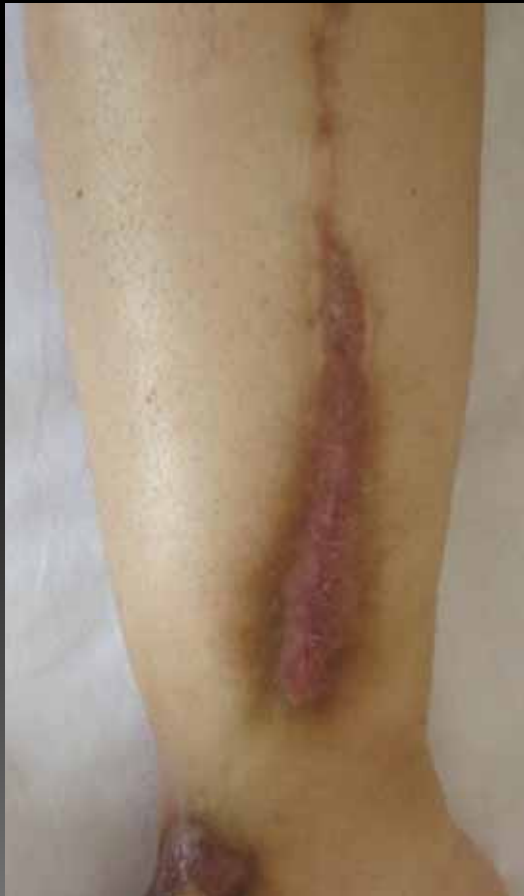
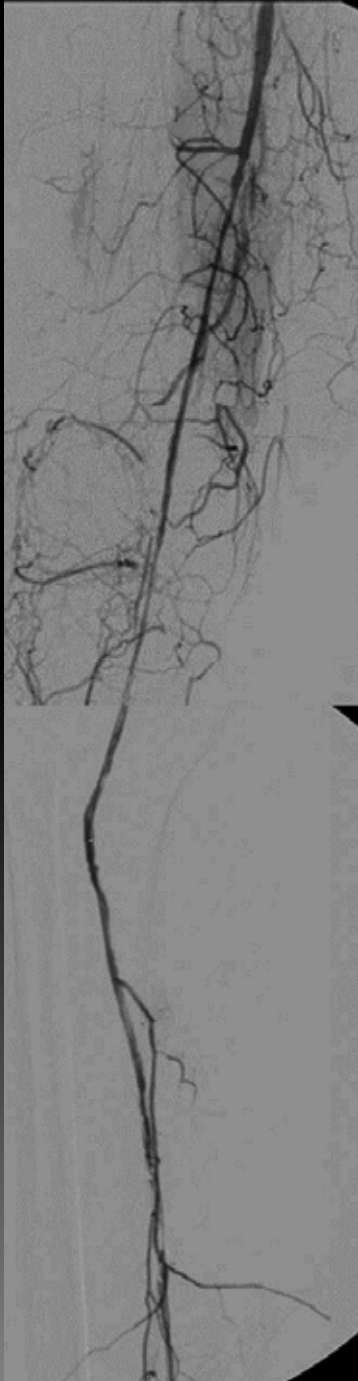Kawarada O, et al. J Endovasc Ther 2013 (in press)



Kawarada O, et al. J Endovasc Ther 2013 (in press)

5 months



Conclusions

- *Showcases of antegrade infrapopliteal CTO recanalization techniques on the atherosclerotic population basis.*
- *Liberal application of contemporary endovascular therapy to Buerger's disease.*